Martini Ziekenhuis Groningen

Longchirurgie voor longkanker

Jan Deroose

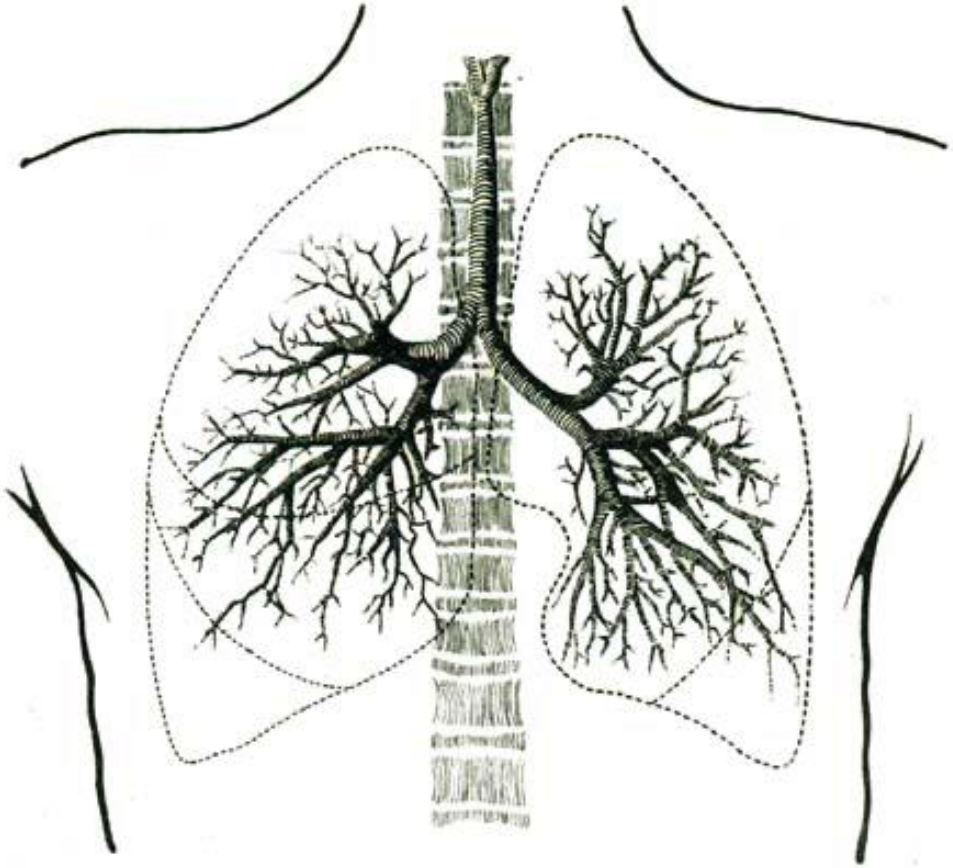

Longcirculatie

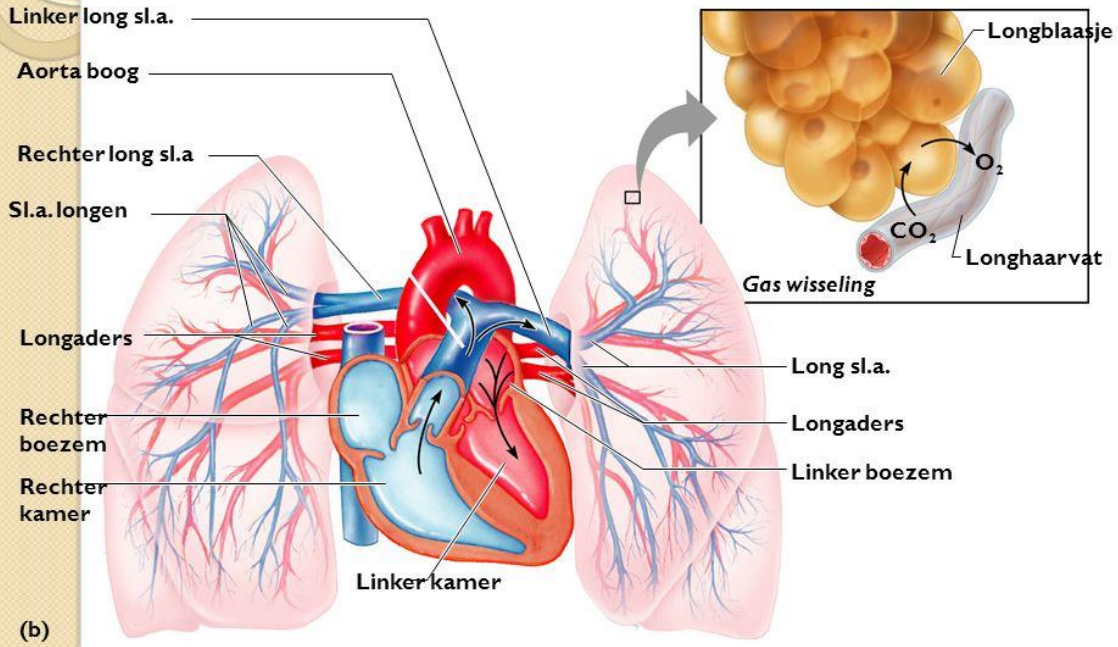

Anatomie thorax

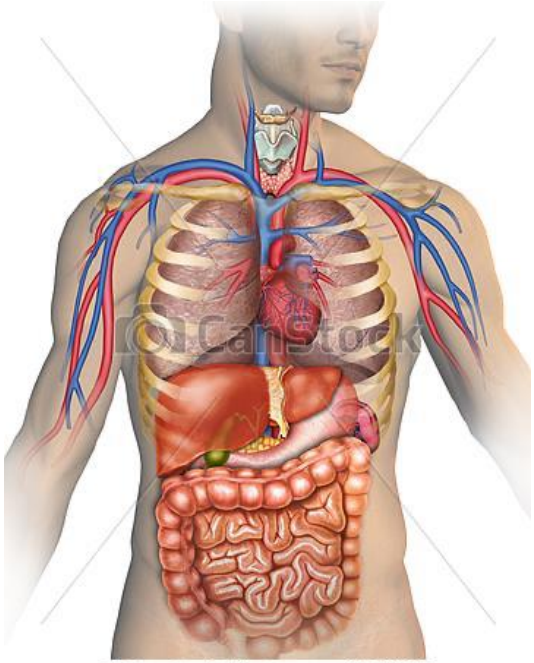

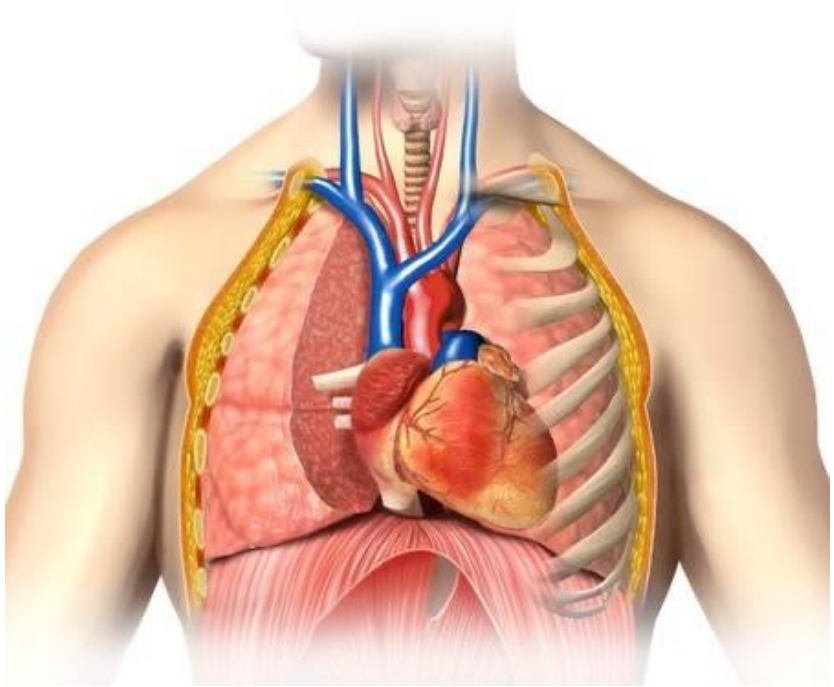

Anatomie long

Anatomie long

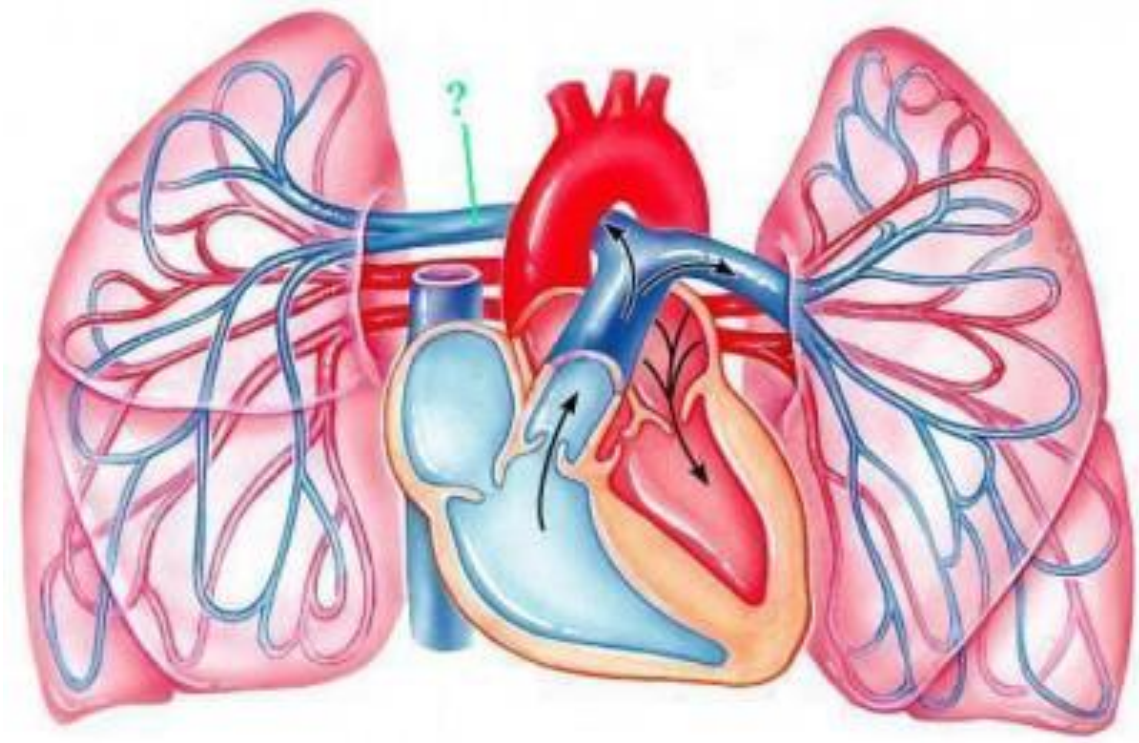

VATS

- VATS: video assisted thoracic surgery
- Minimaal invasieve chirurgie
- Voor het eerste beschreven in 1910
- Huidige toepassing 1993

Hans Christian Jacobaeus (1879-1937)

VATS

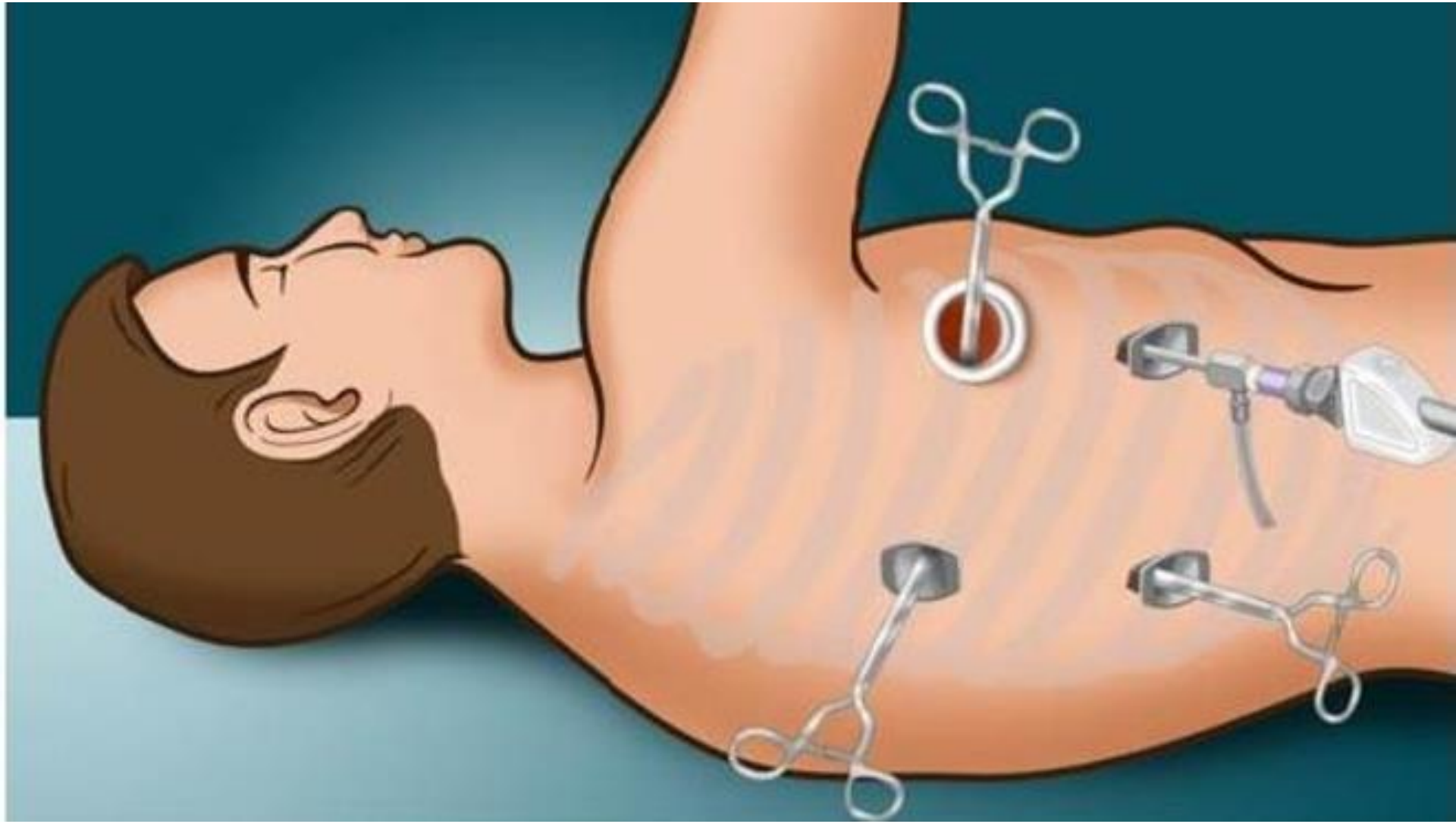

Thoracotomie

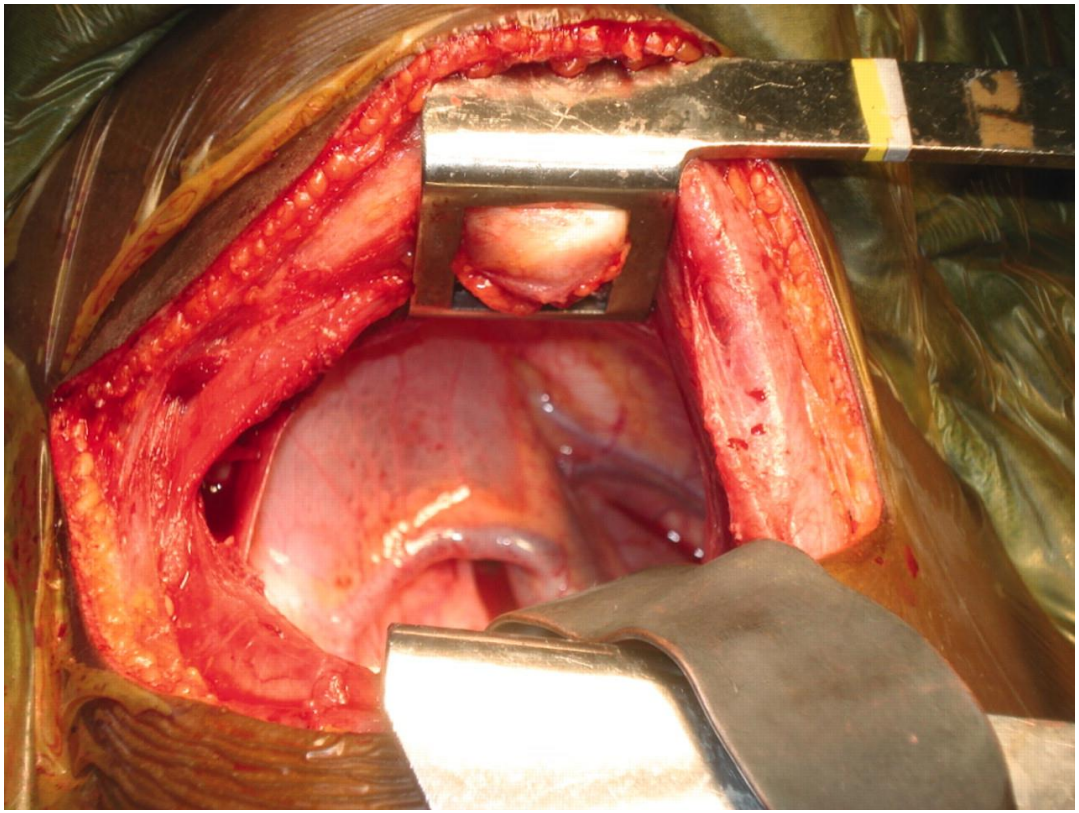

Thoracotomie

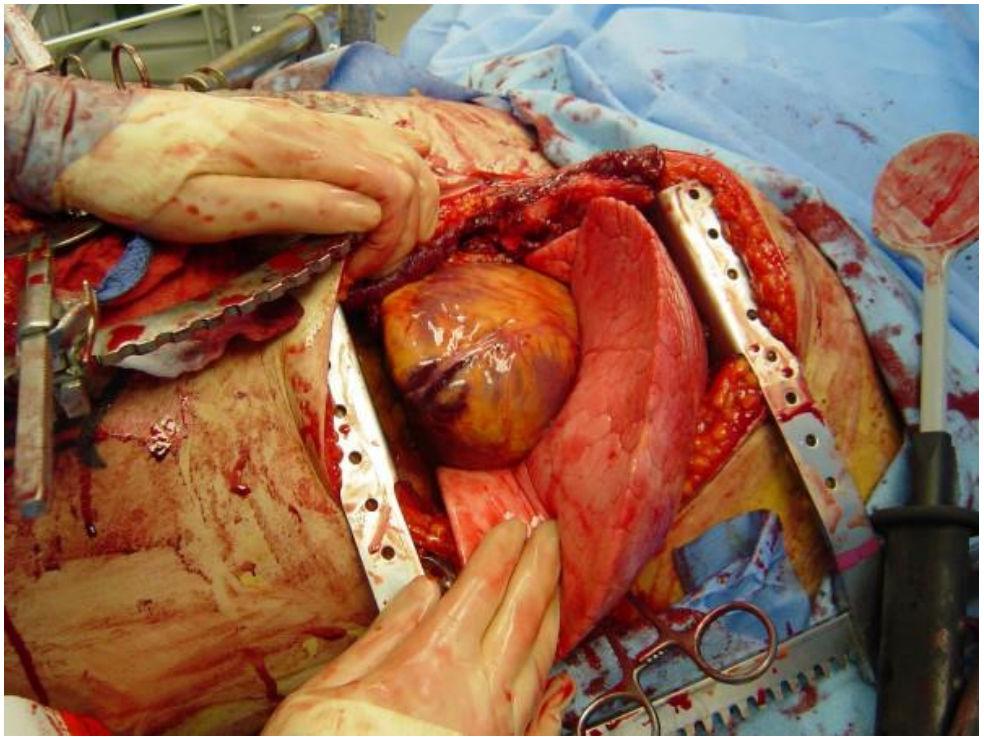

Thoracotomie

Procedure

- Incisie tussen 9de-10de rib
- Een of meerder hulpincisies
  - Geen trocarts
  - Geen CO2

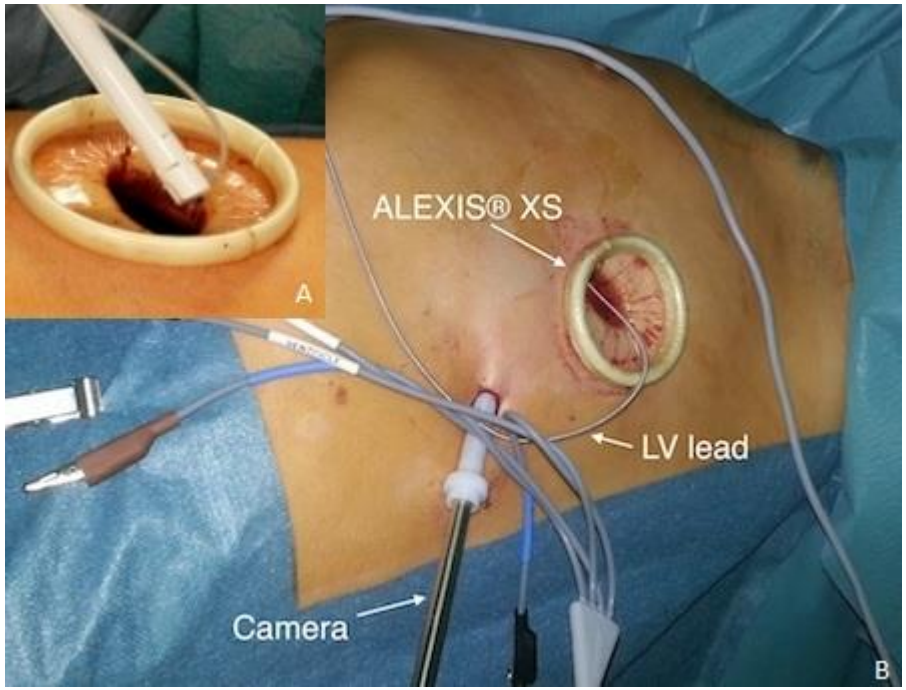

Voordelen

- Geen gerandomiseerde studies
- Theoretische voordelen
  - Niet spreiden van de ribben
  - Wond
  - opname duur
- Realiteit
  - Voordeel op korte termijn
  - Na enkele weken geen verschil

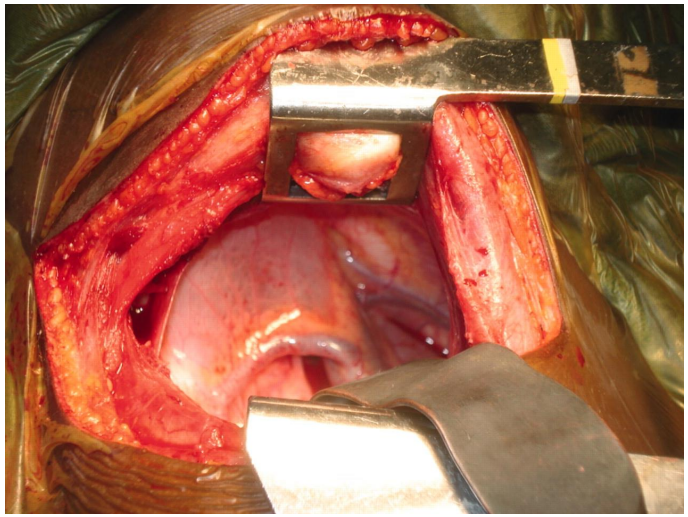

Indicaties longchirurgie

- Biopten
  - Pleura
  - Long
  - Lymfeklieren
- Pleurectomie
- Mediastinale afwijkingen
- Hematothorax
- Thorax empyeem
- Neoplasma long
  - Pulmonale metastasen
  - Primaire neoplasma’s long

Neoplasma’s

- Metastase
- Primaire neoplasma’s
  - Carcinoid
  - Brochuscarcinoom

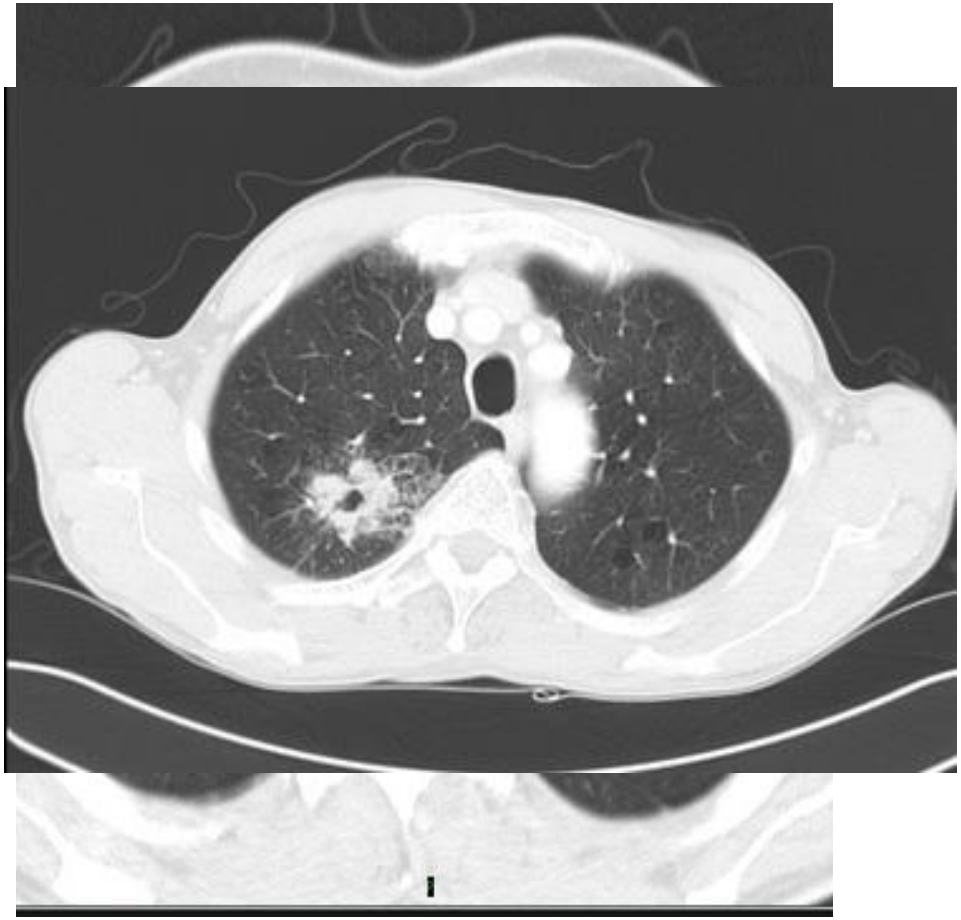

Longkanker

- Vormen
  - Niet kleincellig longcarcinoom
  - Kleincellig longcarcinoom
  - Mesothelioom
- Incidentie
  - 13000 nieuwe patienten per jaar
  - 4de meest voorkomende vorm

Incidentie longkanker

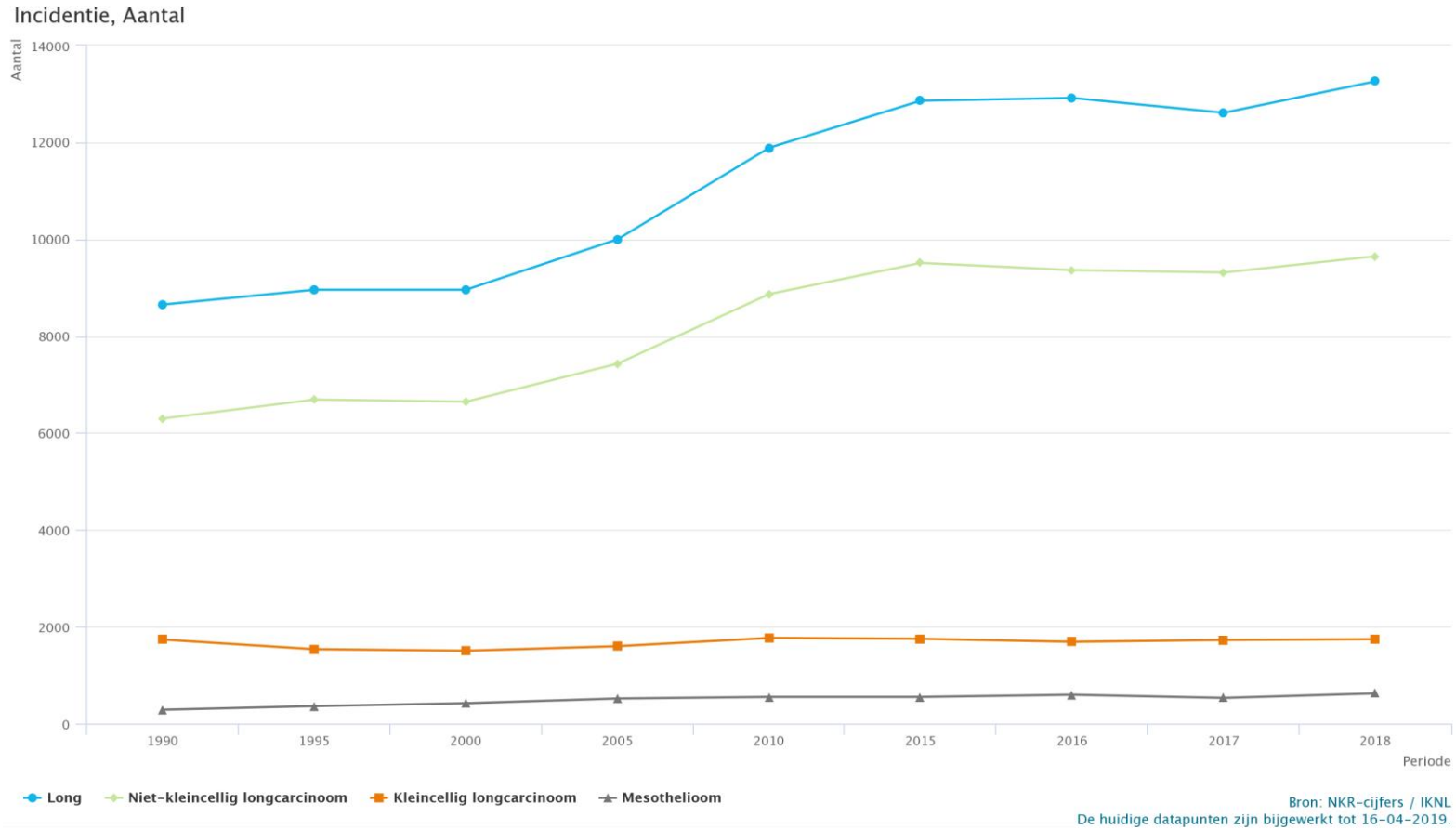

Behandeling stadium I-II

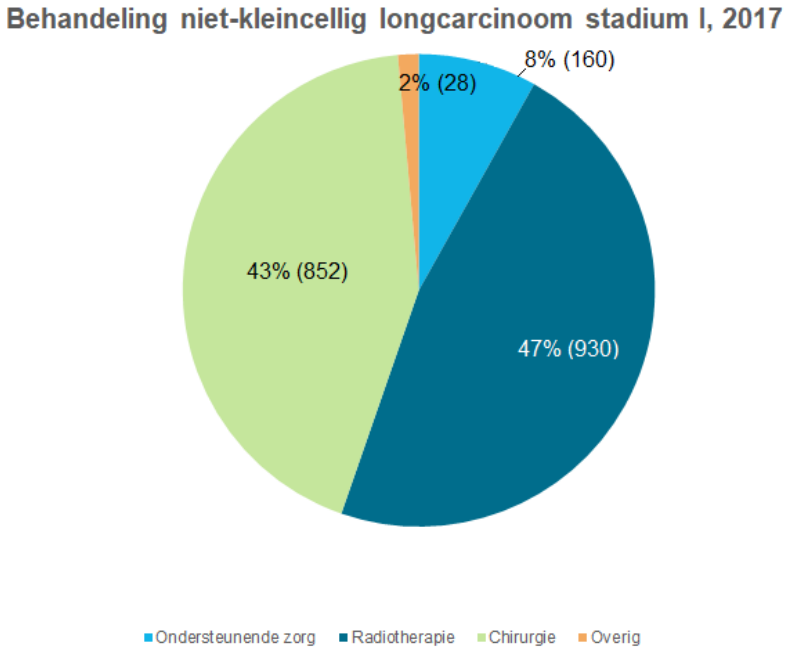

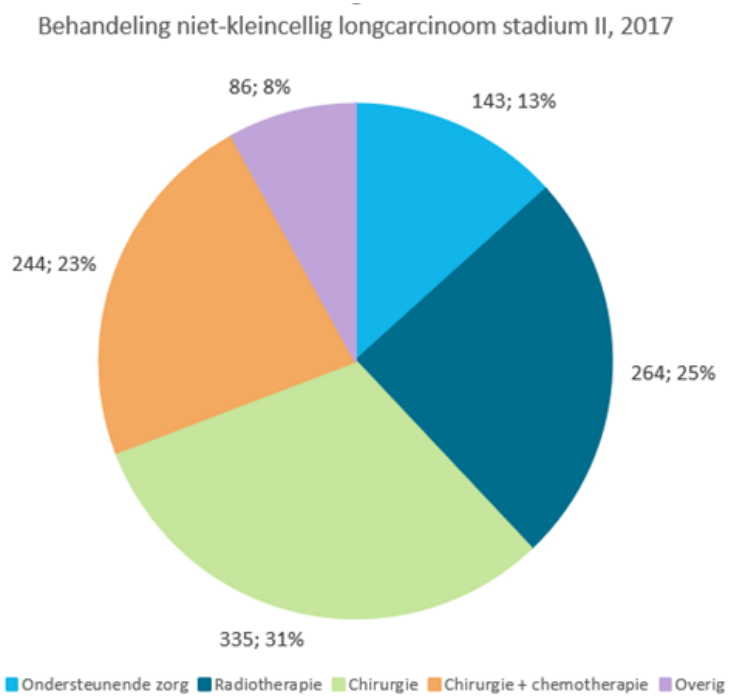

Bronchuscarcinoom

- Anatomische resectie
  - Lobectomie
  - Pneumectomie
- Mediastinale klierdissectie
- Relatieve contra-indicaties VATS
  - Ingroei pleura
  - Grote tumoren
- Absolute contra-indicaties VATS
  - Centrale tumor
  - Na CRTx

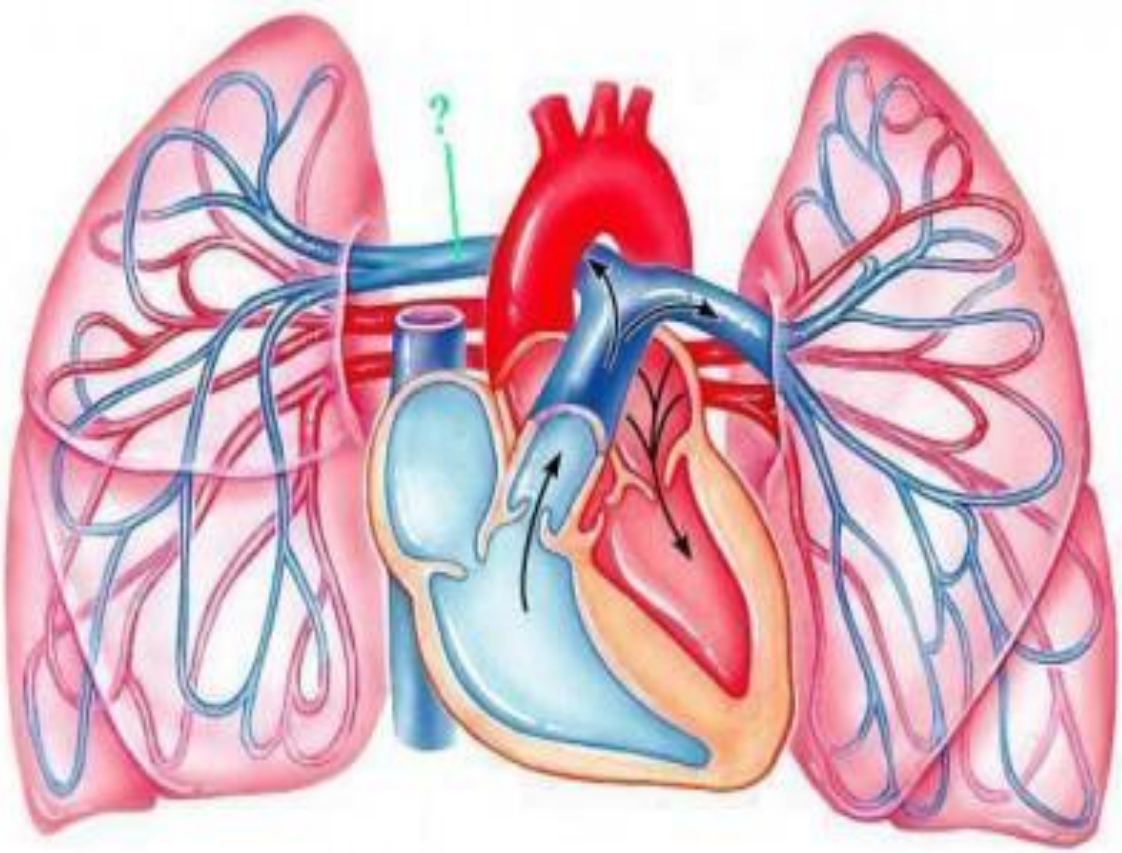

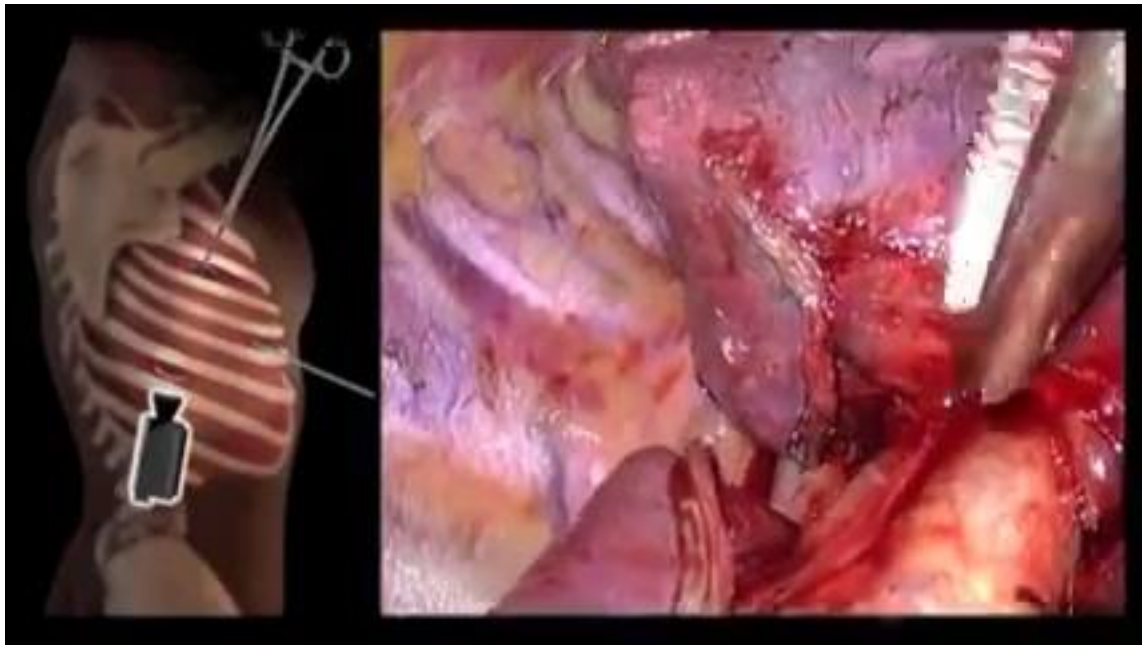

Resultaten
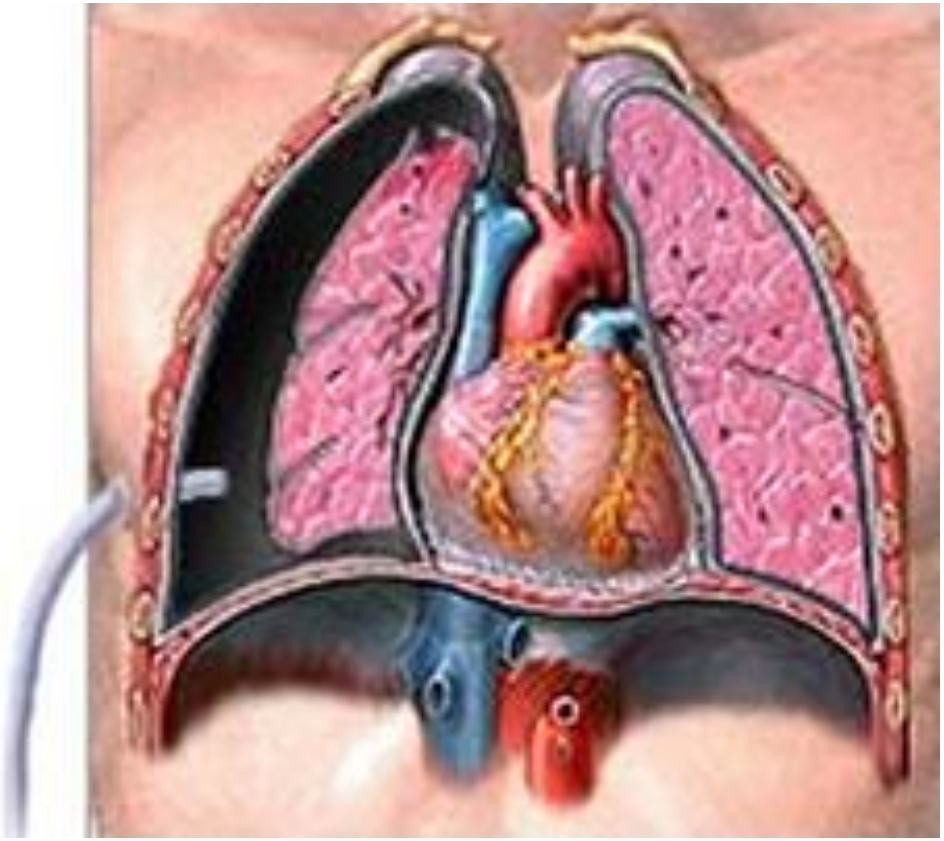
- Mortaliteit 1-2%
- Complicaties <10%
  - Luchtlekkage
  - Longontsteking
- Opnameduur <1 week